

Isolation of *Clostridium tertium* from a Striped Dolphin (*Stenella coeruleoalba*) in the Adriatic Sea

Branka Šeol,^{1,5} Martina Đuras Gomerčić,² Tomo Naglič,¹ Tomislav Gomerčić,³ Ana Galov,⁴ and Hrvoje Gomerčić² ¹ Department of Microbiology and Infectious Diseases, Faculty of Veterinary Medicine University of Zagreb, Heinzelova 55, 10000 Zagreb, Croatia; ² Department of Anatomy, Histology, and Embryology, Faculty of Veterinary Medicine, University of Zagreb, Heinzelova 55, 10000 Zagreb, Croatia; ³ Department of Biology, Faculty of Veterinary Medicine, University of Zagreb, Heinzelova 55, 10000 Zagreb, Croatia; ⁴ Department of Animal Physiology, Faculty of Science, University of Zagreb, Rooseveltov trg 6, 10000 Zagreb, Croatia; ⁵ Corresponding author (email: seol@vef.hr)

ABSTRACT: Bacteriologic examination of an abscess found between blubber and musculature of a striped dolphin (*Stenella coeruleoalba*) found dead on 30 March 2002 in the Adriatic Sea, Croatia, was performed and an aerotolerant, nontoxigenic *Clostridium tertium* was isolated in pure culture. National Collections of Industrial Food and Marine Bacteria (NCIMB Ltd., Aberdeen, Scotland, UK) confirmed the results. Sequencing results showed it to be *C. tertium* with 100% similarity. The strain was named *Clostridium tertium* strain Zagreb, acceded to the culture collection and assigned the accession number NCIMB 13970. This is the first record of *C. tertium* in marine mammals.

Key words: Abscess, Adriatic Sea, *Clostridium tertium*, Croatia, *Stenella coeruleoalba*, striped dolphin.

Striped dolphins (*Stenella coeruleoalba*) are distributed in temperate, subtropical, and tropical seas and are the most common cetacean in the Mediterranean Sea where they typically inhabit offshore waters (Leatherwood et al., 1983). Striped dolphins were first recorded in the Croatian part of the Adriatic Sea in 1991 by Gomerčić et al. (1994), and Bearzi et al. (1998) observed a live specimen in the same area. Bottlenose dolphins (*Tursiops truncatus*) are the only resident cetacean species in the Adriatic Sea; other cetacean species enter occasionally (Gomerčić et al., 1998).

Clostridium tertium is classified as a nontoxin-producing relatively nonpathogenic or low-virulence microorganism, which has been isolated from soil and from feces of healthy neonates and infants (Cato et al., 1986). *Clostridium tertium* is an uncommon human pathogen, first

isolated from war wounds in 1917 by Henry (Cato et al., 1986). It has been isolated in neutropenic as well as non-neutropenic patients (Miller et al., 2001; Tape et al., 2005) and in cases of necrotizing fasciitis and gangrene (Ray et al., 2003). Recently, it has been recognized as a causative agent of enteritis in cattle (Silvera et al., 2003).

On 30 March 2002 in Bay Ruda on the island of Vis, in the south Croatian part of the Adriatic Sea (43°01'N, 16°12'E), a male striped dolphin carcass was found and was transported for postmortem examination to the Department of Anatomy, Histology, and Embryology, Faculty of Veterinary Medicine, University of Zagreb, Croatia. The dolphin was 188 cm long and had a body mass of 66.7 kg. The blubber thickness was 0.8 cm dorsal and 1.0 cm ventral on the transversal line behind the left flipper. According to dentinal growth layer groups in teeth stained by Harris' hematoxylin (Slooten, 1991), the animal was 12 yr old. A gross necropsy was performed; however, brain was not examined because the skull was kept intact as an exhibition specimen. The carcass was in advanced state of decomposition, so the histologic and bacteriologic examinations were performed only on the abscess.

At necropsy, an 18-cm-diameter swelling was observed on the left side of the body, ventral to the base of the dorsal fin. The skin of this region was intact, but there was a 2-cm-thick layer of edema under the blubber that surrounded an abscess consisting of a 2-mm-thick fibrous

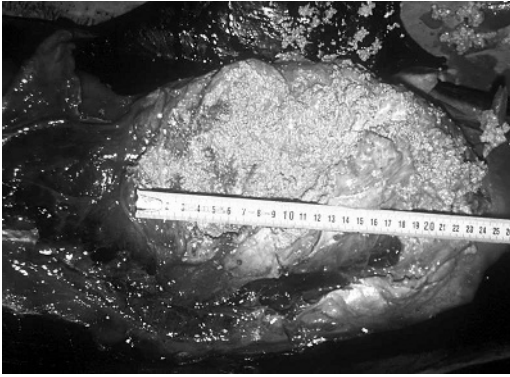


FIGURE 1. Incised abscess caused by *Clostridium tertium* strain Zagreb in subcutis of striped dolphin (*Stenella coeruleoalba*) from the Adriatic Sea with centimeter scale.

capsule surrounding a multichambered space that was $24 \times 13 \times 3$ cm in size and full of pink, dry and gravelly granules (Figs. 1, 2). The edema and abscess were located between the blubber and the musculature. The muscles appeared normal but a radiograph of the underlying part of the vertebral column showed complete lack of the central part of the body of the 12th lumbar vertebra and fusion with bone tissue of the peripheral parts of its body with neighboring (11th and 13th) lumbar vertebral bodies (Fig. 3). Additional findings consisted of a fibrous adhesion of the middle part of the intestine to the parietal peritoneum in the caudal abdominal cavity and an empty stomach. A few parasitic cysts in the blubber of the anal region were examined macroscopically and identified as genus *Phyllobothrium* according to Dailey and Brownell (1972). The abscess was sampled using a sterile swab and a small amount of pink granular material was collected in a sterile container; both were submitted to the Department of Microbiology and Infectious Diseases, Faculty of Veterinary Medicine, University of Zagreb for bacteriologic examination. Samples were streaked onto 5% sheep blood agar (Columbia agar base, Becton Dickinson, Cockeysville, Maryland, USA), and incubated at 37 C for 24 hr under aerobic and anaerobic

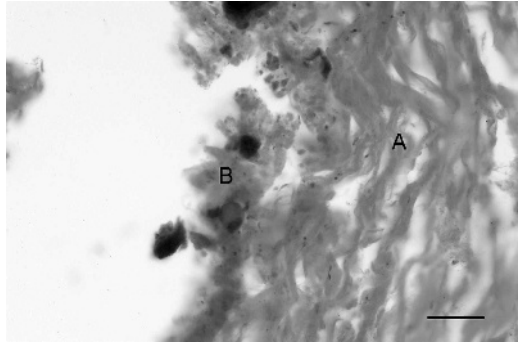


FIGURE 2. Photomicrograph of portion of the abscess capsule showing densely packed connective tissue (A), necrotic cell detritus (B), and small number of bacilli within them. Hematoxylin and eosin stain. Bar=50 μ m.

conditions. A Gram's-stained smear of granules from specimens both revealed large gram-positive rods with large, oval, terminally placed spores. After 24 hr incubation under aerobic and anaerobic conditions, a pure culture of opaque, medium-size colonies were recovered. Although cultures of *C. tertium* often present as gram-negative, especially when cultured under aerobic conditions (Lew et al., 1990), both the aerobic and anaerobic cultures from this striped dolphin were clearly identified as gram-positive non-sporulating rods. Identification of colonies was carried out according to procedure described by Quinn et al. (1994), and using API20 A (bio-Mérieux, Marcy-l'Etoile, France), the isolate was identified as *C. tertium* with a probability of 99.9%.

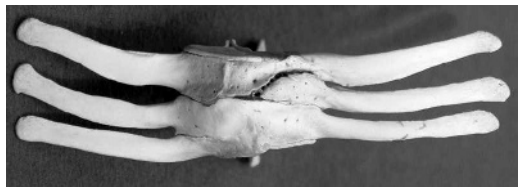

FIGURE 3. Ventral view of fused 11th, 12th, and 13th lumbar vertebrae of striped dolphin (*Stenella coeruleoalba*) from the Adriatic Sea. Old pathologic changes (osteolysis, fusion of vertebral bodies and deviation of vertebral canal) that might be because of previous localized osteomyelitis caused by *C. tertium* strain Zagreb are clearly visible. Bar=5 cm.

The isolated strain was freeze-dried and sent to National Collections of Industrial Food and Marine Bacteria (NCIMB Ltd., Aberdeen, Scotland, UK) for further identification. The 16s RNA sequence analysis demonstrated 100% similarity with *C. tertium*. The strain was named *Clostridium tertium* strain Zagreb, acceded to the culture collection and assigned the accession number NCIMB 13970.

Clostridium tertium infections in animals are rarely described. *Clostridium tertium* has been isolated from the nares of a beagle dog with osteomyelitis, and from an infected calf (Cato et al., 1986). Recently, Silvera et al. (2003) identified 12 isolates of *C. tertium* from calves with enteritis in the UK; these isolates previously had been identified as *Sporolactobacillus* sp. (Al Mashat and Taylor, 1984). Our paper presents the first report of *Clostridium tertium* as a cause of abscessation, osteomyelitis, and death in a dolphin.

The work was supported by grants from the Ministry of Science and Technology of Republic of Croatia and Gesellschaft zur Rettung der Delfine from Munich, Germany, and was carried out according to the annual permission of the Ministry of Environmental Protection and Physical Planning of Republic of Croatia. We also want to thank Peter N. Green and Hedda Weitz from NCIMB Ltd., Aberdeen, Scotland, UK, for sequencing.

LITERATURE CITED

- AL MASHAT, R., AND D. J. TAYLOR. 1984. *Sporolactobacillus* sp. in enteritis in cattle. In Proceeding of the 4th International symposium on neonatal diarrhea. Veterinary Infectious Disease Organization Conference, 3–5 October 1983. University of Saskatoon, Saskatoon, Canada, pp. 654–665.
- BEARZI, G., C. M. FORTUNA, AND G. NOTARBARTOLO DI SCIARA. 1998. Unusual sighting of a striped dolphin (*Stenella coeruleoalba*) in the Kvarnerić, Northern Adriatic Sea. *Natura Croatica* 7: 169–176.
- CATO, E. P., W. L. GEORGE, AND S. M. FINEGOLD. 1986. Genus *Clostridium*. In *Bergey's manual of systematic bacteriology*, Vol. 2, P. H. A. Sneath, N. S. Mair, M. E. Sharpe, and J. G. Holt (eds.). Williams & Wilkins, Baltimore, Maryland, pp. 1141–1200.
- DAILEY, M. D., AND R. L. BROWNELL, JR. 1972. A checklist of marine mammal parasites. In *Mammals of the sea. Biology and medicine*, S. H. Ridgway (ed.). Charles C. Thomas Publisher, Springfield, Illinois, pp. 528–589.
- GOMERČIĆ, H., D. HUBER, T. GOMERČIĆ, A. GOMERČIĆ, D. ŠKRTIĆ, AND S. VUKOVIĆ. 1994. The striped dolphin (*Stenella coeruleoalba*, Meyen, 1833) for the first time found in the Adriatic Sea in 1991. In *Proceedings of abstracts of the papers presented at the 5th Congress of Croatian Biologists*, H. Gomerčić (ed.). Hrvatsko biološko društvo, Zagreb, Croatia, pp. 340–341.
- , ———, A. GOMERČIĆ, AND T. GOMERČIĆ. 1998. Geographical and historical distribution of the cetaceans in Croatian part of the Adriatic Sea. *Rapport du Commission Internationale pour l'Exploration Scientifique de la Mer Méditerranée* 35: 440–441.
- LEATHERWOOD, S., R. R. REEVES, AND L. FOSTER. 1983. *The Sierra Club handbook of whales and dolphins*. Sierra Club Books, San Francisco, California, 302 pp.
- LEW, J. F., B. L. WIEDERMANN, J. SNEED, J. CAMPOS, AND D. MCCULLOUGH. 1990. Aerotolerant *Clostridium tertium* brain abscess following a lawn dart injury. *Journal of Clinical Microbiology* 28: 2127–2129.
- MILLER, D. L., S. BRAZER, D. MURDOCH, L. B. RELLER, AND G. R. COREY. 2001. Significance of *Clostridium tertium* bacteremia in neutropenic and nonneutropenic patients: Review of 32 cases. *Clinical Infectious Diseases* 32: 975–978.
- QUINN, P. J., M. E. CARTER, B. K. MARKEY, AND G. R. CARTER. 1994. *Clinical veterinary microbiology*. Wolfe Publishing, London, UK, 648 pp.
- RAY, P., A. DAS, K. SINGH, A. BHANSALI, AND T. D. YADAV. 2003. *Clostridium tertium* in necrotizing fasciitis and gangrene. *Emerging Infectious Diseases* (serial online). Available from: <http://www.cdc.gov/ncidod/EID/vol9no10/03-0287.htm>. Accessed July 2006.
- SILVERA, M., B. FINN, K. M. REYNOLDS, AND D. J. TAYLOR. 2003. *Clostridium tertium* as a cause of enteritis in cattle. *Veterinary Record* 156: 60.
- SLOOTEN, E. 1991. Age, growth, and reproduction in Hector's dolphins. *Canadian Journal of Zoology* 69: 1689–1700.
- TAPE, D., J. DIRKS, R. MULLER, J. BREDERLAU, M. ABELE-HORN, S. SUERBAUM, AND O. KURZAI. 2005. Fatal *Clostridium tertium* septicaemia in a non-neutropenic patient. *Journal of Infection* 50: 76–80.

Received for publication 20 June 2005.